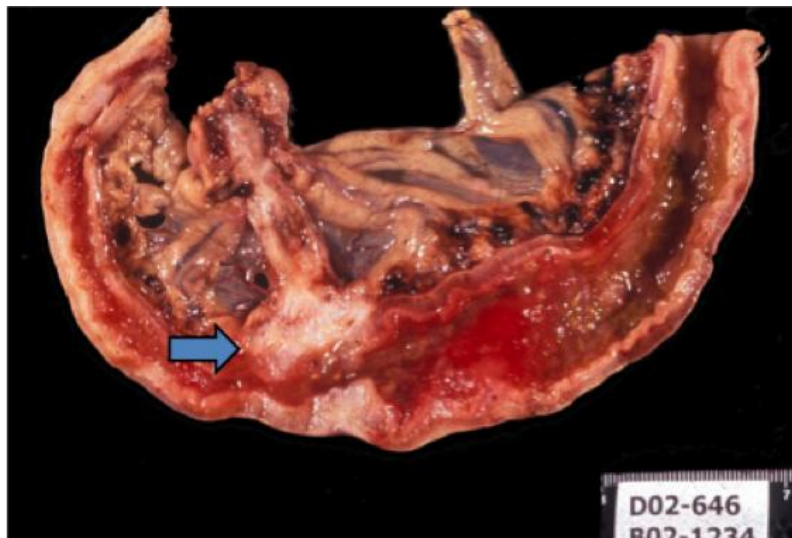


NEOPLASIA I: Benign and malignant neoplasms in glandular epithelium, mesenchyme and haematopoietic tissue – Examples in Veterinary Medicine

INTESTINAL ADENOMA – ADENOCARCINOMA.

Primary intestinal tumours can be epithelial, neuroendocrine, haematopoietic or mesenchymal in origin. Intestinal neoplasms are diagnosed most frequently in dogs, cats and horses mainly because of their longer life span. Adenomas or adenomatous polyps and adenocarcinomas are most commonly diagnosed.

The photograph illustrates a colonic adenocarcinoma (arrow) from a dog. The neoplasm has invaded the intestine wall. Look at the section on the web site where islands of cells and glandular structures are present through the muscularis mucosa, submucosa, tunica muscularis and serosa.



Colon carcinoma: P2009-427A

Catalogue Number	Scanned Image
Colon carcinoma: P2009-427A	Colon carcinoma: P2009-427A

SUBCUTANEOUS SARCOMA

In cats vaccine-associated sarcomas (e.g. fibrosarcoma) account for about 40% of all feline skin tumours and are the most frequent skin tumour in this species. Vaccine-associated sarcomas are aggressive, often rapidly growing neoplasms. The pathogenesis is believed to involve chronic local inflammation, which has been associated with the adjuvant in the vaccines and age related immunodeficiency. The picture below shows a highly invasive neoplasm. There is less of an association between vaccination and soft tissue sarcomas in dogs.

