

**PROBLEM-SOLVING EXERCISE: INFLAMMATION & REPAIR
PEPTIC ULCER**

ANSWER SHEET

Part One

1. *Picture A is a macroscopic view of a portion of the stomach viewed from the mucosal surface.*

Catalogue Number	Small Image	Image Map	Large Image
A_CI_UL_ST_17.jpg	Picture A	Image map	Picture A

2. *Describe the main pathological feature.* Within the centre of the portion of stomach, there is a large oval shaped **peptic ulcer**, with a crisply punched out margin. The base of the ulcer shows necrotic slough, with a central, large, dilated blood vessel.

3. *Pictures B, C, D are microscopic views.*

Catalogue Number	Small Image	Image Map	Large Image
A_CI_UL_ST_18.jpg	Picture B	Image map	Picture B
A_CI_UL_ST_19.jpg	Picture C	Image map	Picture C
A_CI_UL_ST_20.jpg	Picture D	Image map	Picture D

4. *From where would these histological sections be taken in relation to picture A?*

Picture B (low power) is taken from the edge of the ulcer and it shows (on the right of the picture) the mucosal epithelium undergoing **regeneration** (it is this epithelial regenerative component that gives the crisply punched out appearance to the ulcer to the naked eye). To the left of picture B the ulcer base is seen to consist of necrotic slough with underlying inflammation.

Picture C (low power) shows the **zonal pattern** of the ulcer base, with a superficial zone of necrotic slough at the surface, an inflammatory zone in the middle, and at the bottom there is a zone of **repair** with fibrous scarring extending into the muscular layers of the stomach wall. To the left of the picture, there is a dilated, large arterial blood vessel (corresponding to the large blood vessel seen in picture A).

Picture D shows a medium power view of the **zonal pattern** of the ulcer base with **necrotic slough** near the surface with a **fibrinous exudate**. Underneath this, there is a zone of **inflamed granulation tissue**, in which a mixture of capillary blood vessels and fibrous tissue can be discerned. Under that is a zone of **granulation tissue with scarring** (with some chronic inflammation) extending into the muscle wall of the stomach.

5. *Picture E is a high power view of an area of picture D.*

Catalogue Number	Small Image	Image Map	Large Image
A_CI_UL_ST_21.jpg	Picture E	Image map	Picture E

6. *What are the components of this tissue?* Picture E shows a high power view of the zone of inflamed granulation tissue. You can make out the dilated capillary blood vessels, containing red blood cells and occasional marginating neutrophils. In between the capillaries there are spindle shaped

fibroblasts laying down collagen (forming fibrous tissue - repair). Within the fibrous tissue there is an infiltrate of inflammatory cells, mostly neutrophils (acute inflammation) with some macrophages and lymphocytes (chronic inflammation). This is **acutely & chronically inflamed granulation tissue** seen within the superficial and middle zone of the ulcer base.

7. *From the above macroscopical and microscopical observations, what do you deduce about the nature of this disease?* There is evidence of persistent or recurrent injury (gastric acid and enzymes) leading to cell death by necrosis at the superficial part of the ulcer. This triggers an acute inflammatory response, leading on to chronic inflammation with granulation tissue, leading to laying down of fibrous tissue and subsequent scarring. This is therefore an example of **acute inflammation, chronic inflammation and repair**.

Part Two

Doctors have treated this disease in the following ways: peptic ulceration results from a disturbance in the usual balance between the **mucosal defences** of the stomach wall (a mucus layer on the epithelium) and attack by **gastric acid**. Initially, infection by the bacterium *Helicobacter pylori* may induce inflammation of the stomach and directly upset this balance allowing chemical attack of the gastric wall by acid.

Discuss the rationale behind each of these.

1. *Advice on diet and way of life, to include small but frequent meals, additional alkaline foods (e.g. milk), and avoidance of aspirin.* It is important to think about aggravating factors that induce increased production of gastric acid, which then attacks the stomach wall/ulcer base causing persistent or recurrent chemical injury, leading to further cell death and inflammatory responses. Ways of reducing gastric acid production, or neutralising gastric acid once it has been secreted include small but frequent meals in particular those with alkaline foods such as milk. Aspirin, and other non-steroidal anti-inflammatory drugs (NSAIDs), can chemically damage the gastric wall, aggravating peptic ulceration so these should be avoided. Other aggravating factors (that increase acid or reduce defences) include smoking, alcohol, spicy foods, and stress – all should be avoided if possible.

2. *An operation in which both vagus nerves were cut as they run towards the stomach, and a portion of the stomach was removed.* Gastric acid is secreted by parietal cells in the body (and fundus) of the stomach. One of the major influences on gastric acid secretion is the parasympathetic nervous supply running through the vagus nerves to the stomach wall. Therefore, surgical interruption of the vagus nerves can cut out this nervous stimulus to gastric acid secretion. Resection of part or all of the body and fundus of the stomach would also have the effect of removing those parts of the stomach containing parietal cells that secrete acid. Both of these treatments reduce acid within the stomach, cutting down the persistent or recurrent chemical injury, allowing the peptic ulcer to heal.

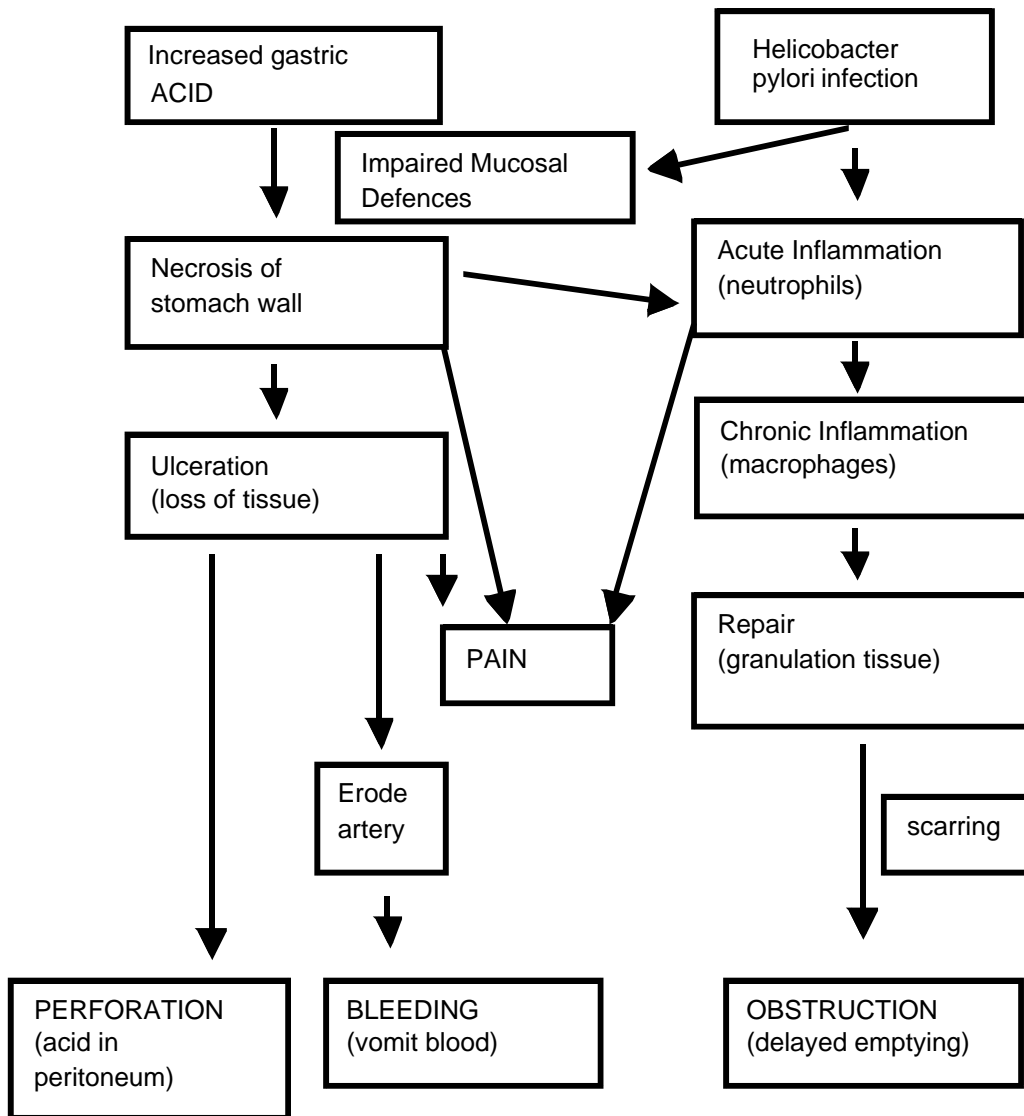
3. *Tablet treatment with either a histamine H₂ receptor antagonist or a proton pump inhibitor.* Another important influence on gastric acid secretion is the stimulatory effect of histamine on the H₂ receptor on the acid-producing parietal cells. Drugs are available to block this interaction between the ligand (histamine) and its receptor (the H₂ receptor), such as cimetidine. Other drugs are also available that can inhibit the proton pump in the parietal cells responsible for the secretion of acid, such as omeprazole.

4. *Tablet treatment with antibiotics.* As one of the key initiating factors causing inflammation of the stomach (gastritis) is the bacteria *Helicobacter pylori*, then it makes sense to attempt to eradicate this bacterial infection (if present) with antibiotics such as amoxicillin or metronidazole. Usually these

drug treatments are combined: using an acid-reducing drug such as either an H₂ receptor blocker or proton pump inhibitor, plus 1 or more antibiotics.

Part Three

Sketch out a flow diagram, linking the aetiology and pathogenesis of this disease to its presentation, the subjective symptoms the patient might have felt, and the physical signs of disease he or she might have exhibited.



Part Four

What other disease of the stomach could have a similar appearance? A cancer (an unregulated growth of cells) in the wall of the stomach could also ulcerate giving a similar appearance to the naked eye (or looking at the internal lining of the stomach in the patient with a fibre-optic instrument – endoscope).

How would you distinguish between them? A biopsy (a small fragment of tissue taken with a “grabbing” instrument using an endoscope) could be taken from the stomach of the patient, fixed and processed to make a slide of a section stained with haematoxylin & eosin. Microscopic examination of the slide would allow you to see if there were cancer cells present or whether there was acute and chronic inflammation with repair.