

### AIMS

1. To develop an understanding of acute inflammation as a major pathological process involved in the response to injury and infection.
2. To understand how the cells involved in innate and adaptive immunity originate in the bone marrow, travel through the blood and migrate into the tissues.
3. To recognise the neutrophil as the key cell of acute inflammation.
4. To develop the skills of description and interpretation of pathological changes in tissue sections, with emphasis on the identification of pathological processes.

### INTRODUCTION

Nature has evolved a variety of sophisticated and subtle processes by which danger to the survival of an organism is recognised, challenged and, hopefully, overcome. These processes constitute two overlapping sets of reactions and their effects and are called innate and adaptive immunity (immunity means protection). Innate immunity is an immediate, albeit relatively non-specific response to danger and is elicited by tissue damage, e.g. at a site of injury or at a focus of infection. The reaction is termed inflammation.

### ACUTE INFLAMMATION

Acute inflammation is the local response elicited by tissue damage. A characteristic feature is leakage of blood proteins into the tissue (predominantly fibrinogen, which is quickly converted to fibrin) and the recruitment of leukocytes from the blood. Together these constitute an inflammatory exudate. The first leukocytes to be recruited are neutrophils (NPLs), also called polymorpho-nuclear leukocytes (PMNLs) and these are characteristic cellular markers of acute inflammation.

The central aim of today's practical is to recognise the characteristic histological features (footprint) of acute inflammation by the identification of neutrophils and fibrinous exudate in pneumonia (acute inflammation in the lung).

As time passes following acute injury other leukocytes are recruited into the tissue, e.g. lymphocytes and monocytes and these give rise to the characteristic pattern of chronic inflammation. These features, along with the processes of organisation of dead tissue and of repair will be dealt with in later classes.

It should be remembered that all of the leukocytes that enter tissues in any form of inflammation are derived from the pool of circulating cells in the blood. The predominant leukocyte in normal blood is the neutrophil. It is readily recognisable by a poly-lobated nucleus. When it enters the tissue this characteristic morphology is still recognisable, but, as the cells begin to die, the poly-lobated structure of the nucleus is less obvious (why might this be?).

Catalogue Number	Small Image	Image Map	Large Image
N_CS_NU_09.jpg	<a href="#">Neutrophils in tissue</a>	<a href="#">Image Map</a>	<a href="#">Neutrophils in tissue</a>

## A NORMAL BLOOD FILM

Although most of the classes that deal with the appearance in disease are based around tissue sections, cells can also be visualised in films or smears of biological fluids. Seen this way, whole cells rather than a section through them are represented and it is often easier to recognise details of cellular structures such as the nucleus. Before studying neutrophils in a tissue section, therefore, it is useful to identify them in a blood film.

Look at the thin end of the film where the cells are well spread out. Notice :

- (i) Red blood cells (RBCs; erythrocytes) which are round, anucleate, and have a pale biconcave centre
- (ii) Leukocytes, the predominant cell being the neutrophil.
- (iii) What are the other cell types?

### H1 Normal blood film 86.547 or 96.354

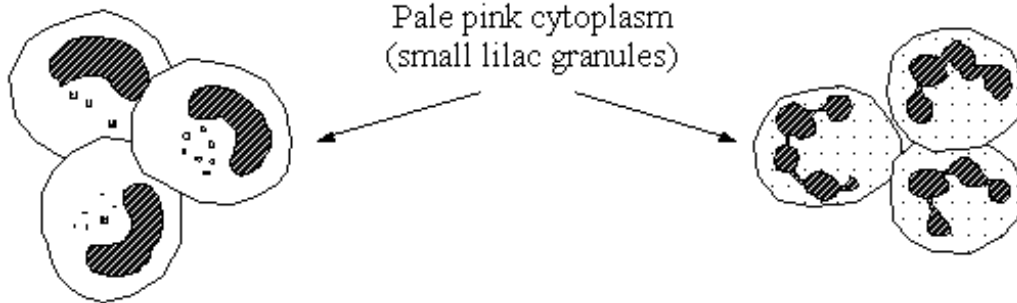
Catalogue Number	Small Image	Image Map	Large Image
N_HL_BF_09.jpg	<a href="#">Blood film</a>	<a href="#">Image Map</a>	<a href="#">Blood film</a>

The following diagram shows schematic drawings of the cells seen in the blood (to help you identify the different cell types). These are the cells of the haematopoietic and immune system. The second diagram (on the following page) shows how the immune system cells derive from precursors in the bone marrow (myeloid and lymphoid series of cells in particular). From there, they enter and travel through the blood (where we can sample them using “the blood film” technique you are examining now), allowing them to migrate to the site where they are needed. They can then enter the tissues becoming mature cells ready to carry out the effector functions of the **innate immune system (myeloid cells: granulocytes and monocytes)** and the **adaptive immune system (lymphoid cells: B lymphocytes/plasma cells and T lymphocytes – with the one exception that some lymphoid precursors form NK cells which act as part of the innate immune system)**.

# Leukocytes in Peripheral Blood

## (1) Granulocytes

(a) Neutrophils (polymorphonuclear leukocytes, PMNL)



Immature ('band' forms)


Mature forms

(b) Eosinophils



Large dull red granules  
(bilobed nucleus)

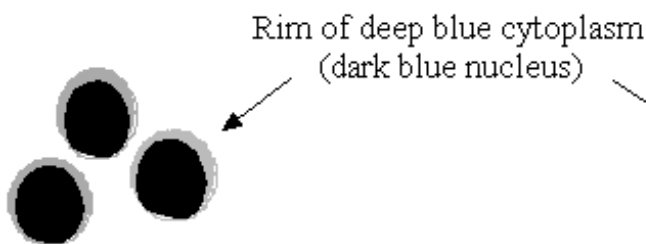
(c) Basophils



Very basophilic granules  
obscuring kidney-shaped  
nucleus

## (2) Mononuclear cells

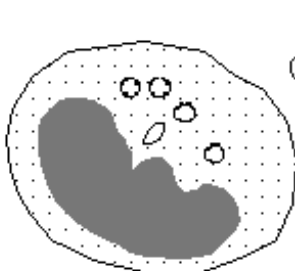
(d) Lymphocytes



(e) Large lymphoid cells



(f) Monocytes

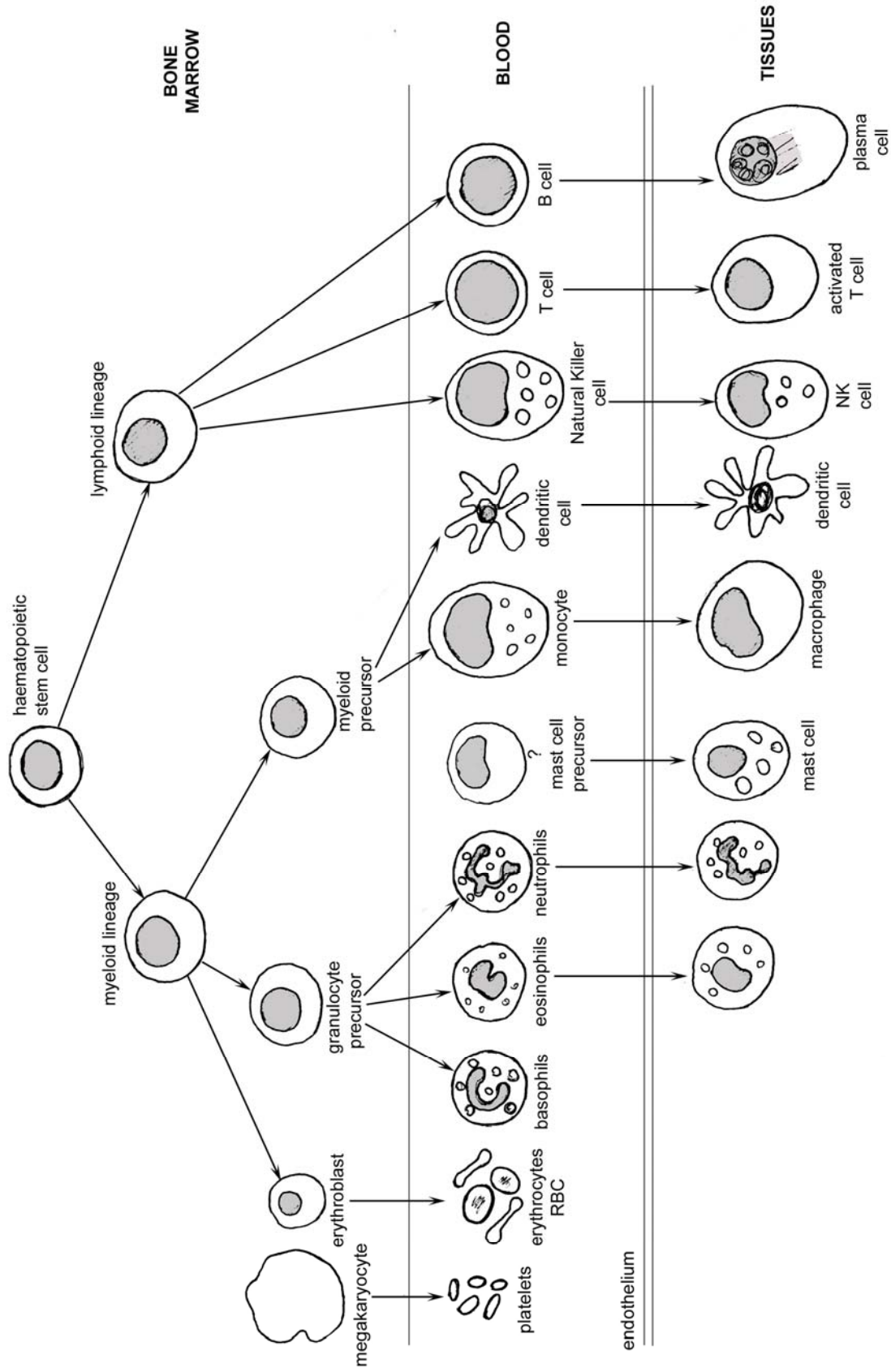


Pale blue abundant cytoplasm  
(clear vacuoles may be present)

Red blood cells (for  
comparison of size)



**Derivation of circulating blood cells & certain tissue leukocytes from haemopoietic bone marrow stem cells**



## A CASE OF BRONCHOPNEUMONIA

You are provided with sections of normal lung for reference and a case of acute bronchopneumonia. Look for evidence of an acute inflammatory exudate, noting the large number of neutrophils in the bronchial tree and in the alveoli and also the presence of fibrin.

### CR8      Normal lung: for reference 70.16A

Catalogue Number	Small Image	Image Map	Large Image
N_CR_LU_02.jpg	<a href="#">Normal lung</a>	<a href="#">Image Map</a>	<a href="#">Normal lung</a>

### 2.1      Lung: bronchopneumonia 80.226

Catalogue Number	Small Image	Image Map	Large Image
A_AI_BP_LU_01.jpg	<a href="#">Bronchopneumonia</a>	<a href="#">Image Map</a>	<a href="#">Bronchopneumonia</a>
A_AI_BP_LU_08.jpg	<a href="#">Bronchopneumonia</a>		<a href="#">Bronchopneumonia</a>
A_AI_BP_LU_20.jpg	<a href="#">Bronchopneumonia</a>		<a href="#">Bronchopneumonia</a>
A_AI_BP_LU_27.jpg	<a href="#">Bronchopneumonia</a>		<a href="#">Bronchopneumonia</a>
A_AI_BP_LU_38.jpg	<a href="#">Bronchopneumonia</a>		<a href="#">Bronchopneumonia</a>

In the centre of this section, viewed with the naked eye, there is a dark, Y-shaped structure. Start here. It is a longitudinal section through a bronchus at a branch-point, but it is abnormal in that its lumen is filled with inflammatory cells. Almost all these cells are neutrophil leukocytes. You can make out two- and three-lobed nuclei, but they do not have quite the same appearance as the cells you identified as neutrophils in the blood film. This is because the cells in the blood film were spread out flat, whereas here they have been sliced through during the preparation of the section. Now look further afield, first immediately around the bronchus, and then all over the section.

Compare the normal and patchily inflamed lung, both with the naked eye and under the microscope. Bacterial infection beginning in the respiratory tree has provoked an inflammatory response and many leukocytes, mainly neutrophils, have migrated from the blood into the lung. They are in the small bronchi, where many are dying or dead, and also in some adjacent alveoli.

Large areas look **red** because of **vasodilatation** and **haemorrhage**. Haemorrhage occurs commonly into the lung in bronchopneumonia and probably indicates tissue injury by the bacteria. Study the erythrocytes in the section with care and distinguish those, in their normal place, within the thin walled blood vessels from those in the alveolar air spaces. The bronchial epithelium has become detached in places. You can see other changes brought about by inflammatory mediators. There is **dilatation of the blood vessels**; this is difficult to appreciate and a comparison with the normal lung will help you. Note the pale pink homogeneous material which is **fluid exudate** containing protein (particularly fibrin) in some alveoli, which prevents their normal expansion.

Quite extensive areas of the lung parenchyma could not expand because of the exudate and this has resulted in poor exchange of oxygen and carbon dioxide. The patchy pattern of inflammation involves the bronchi and the adjacent lung parenchyma; it is therefore called '**BRONCHOPNEUMONIA**'. Note black granules of inhaled carbon, often around the bronchi and within the lung macrophages (this is normal).

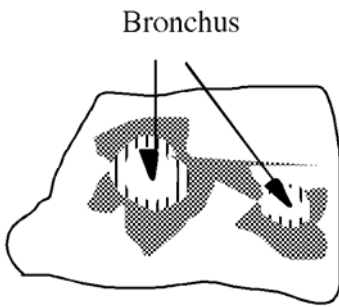
From a 30 year-old woman who died after an attack of acute bronchopneumonia.

It should be noted that the areas of abnormality in bronchopneumonia are patchy. Pneumonia may also occur as a diffuse inflammation affecting a large area of a lobe of the lung. This is lobar pneumonia.

The different types of acute inflammation of the lung are illustrated in the figure below.

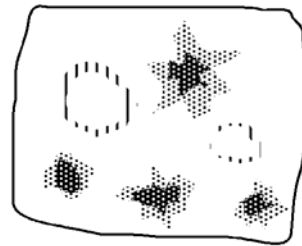
**LOW POWER appearance of some types of acute inflammation in the lung**

BRONCHOPNEUMONIA



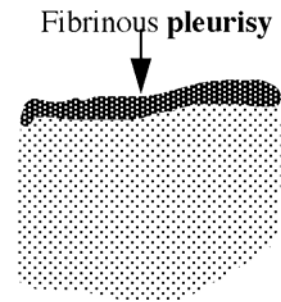
Broncho-centric patches

BLOOD-BORNE INFECTION



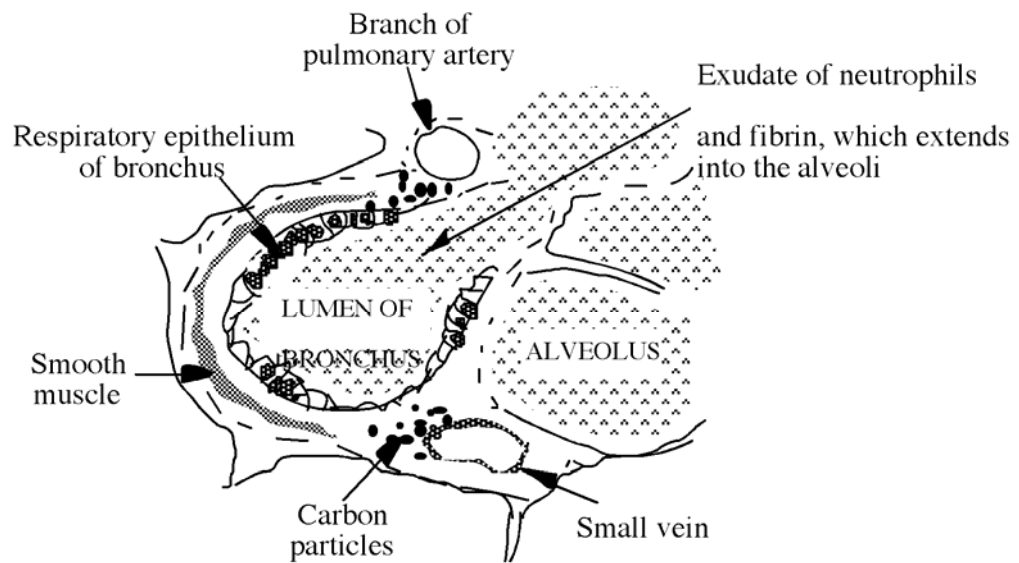
Patches of inflammation **NOT** related to bronchi

LOBAR PNEUMONIA



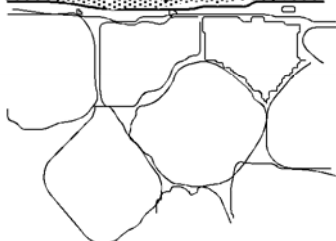
Diffuse involvement of lung parenchyma

**HIGH POWER of BRONCHOPNEUMONIA**



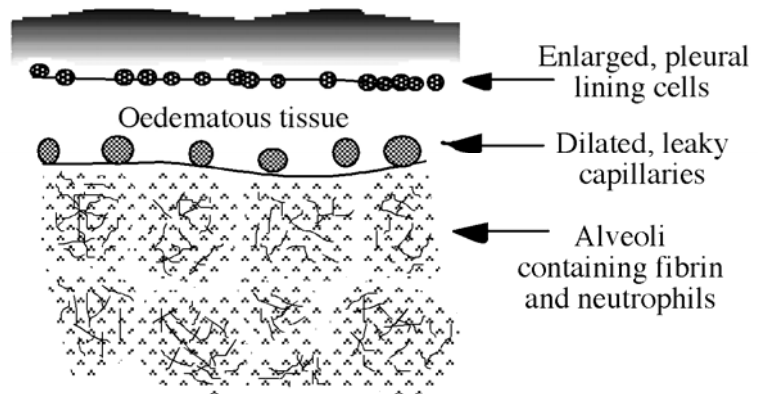
NORMAL LUNG

Flat pleural cells, no exudate or oedema; tiny blood vessels



**HIGH POWER of LOBAR PNEUMONIA**

Compacted fibrin constitutes fibrinous pleurisy



## 65.140 or 62.38

Catalogue Number	Small Image	Image Map	Large Image
A_AI_PN_LU_01	<a href="#">Lobar pneumonia</a>		<a href="#">Lobar pneumonia</a>
A_AI_PN_LU_10	<a href="#">Lobar pneumonia</a>		<a href="#">Lobar pneumonia</a>
A_AI_PN_LU_05	<a href="#">Lobar pneumonia</a>		<a href="#">Lobar pneumonia</a>
A_AI_PN_LU_08	<a href="#">Lobar pneumonia</a>		<a href="#">Lobar pneumonia</a>
A_AI_PN_LU_07	<a href="#">Lobar pneumonia</a>		<a href="#">Lobar pneumonia</a>

This is an **acute inflammatory process**, which even in a single section, is seen to be diffuse contrasting with the patchiness of bronchopneumonia.

**LOBAR PNEUMONIA** refers to rapidly spreading inflammation which can develop in infections by bacteria which have thick capsules, e.g. pneumococci, which have polysaccharide capsules. The lung parenchyma quickly fills with proteinaceous fluid and leukocytes and when the infection reaches the pleura, this in turn becomes inflamed and fibrinogen leaks from blood vessels onto the surface. This is converted to fibrin which coats the lung as fibrinous pleurisy. Which type of leucocyte will arrive first at the infection?

Fibrin within the alveoli appears as delicate threads, but over the pleura, respiratory movements cause it to be compacted. Notice that although all the alveoli contain an inflammatory exudate, the alveolar walls are intact.

Contrast this with the tissue damage which had occurred in the previous section of bronchopneumonia (**Slide 2.1**).

The tissue seen here is from a 53 year old homeless person who died, having been breathless for a few days, and who had not sought any medical attention.

### 2.3 Lung: Lobar pneumonia (Trichrome stain) 62.38

Catalogue Number	Small Image	Image Map	Large Image
A_AI_PN_LU_06	<a href="#">Lobar pneumonia</a>		<a href="#">Lobar pneumonia</a>
A_AI_PN_LU_13	<a href="#">Lobar pneumonia</a>		<a href="#">Lobar pneumonia</a>

This special stain is a mixture of three dyes and is used to **stain fibrin scarlet**.

(Look for the red network in the air spaces).

Connective tissue and other elements are blue; red blood cells vary in colour, from orange to yellow.

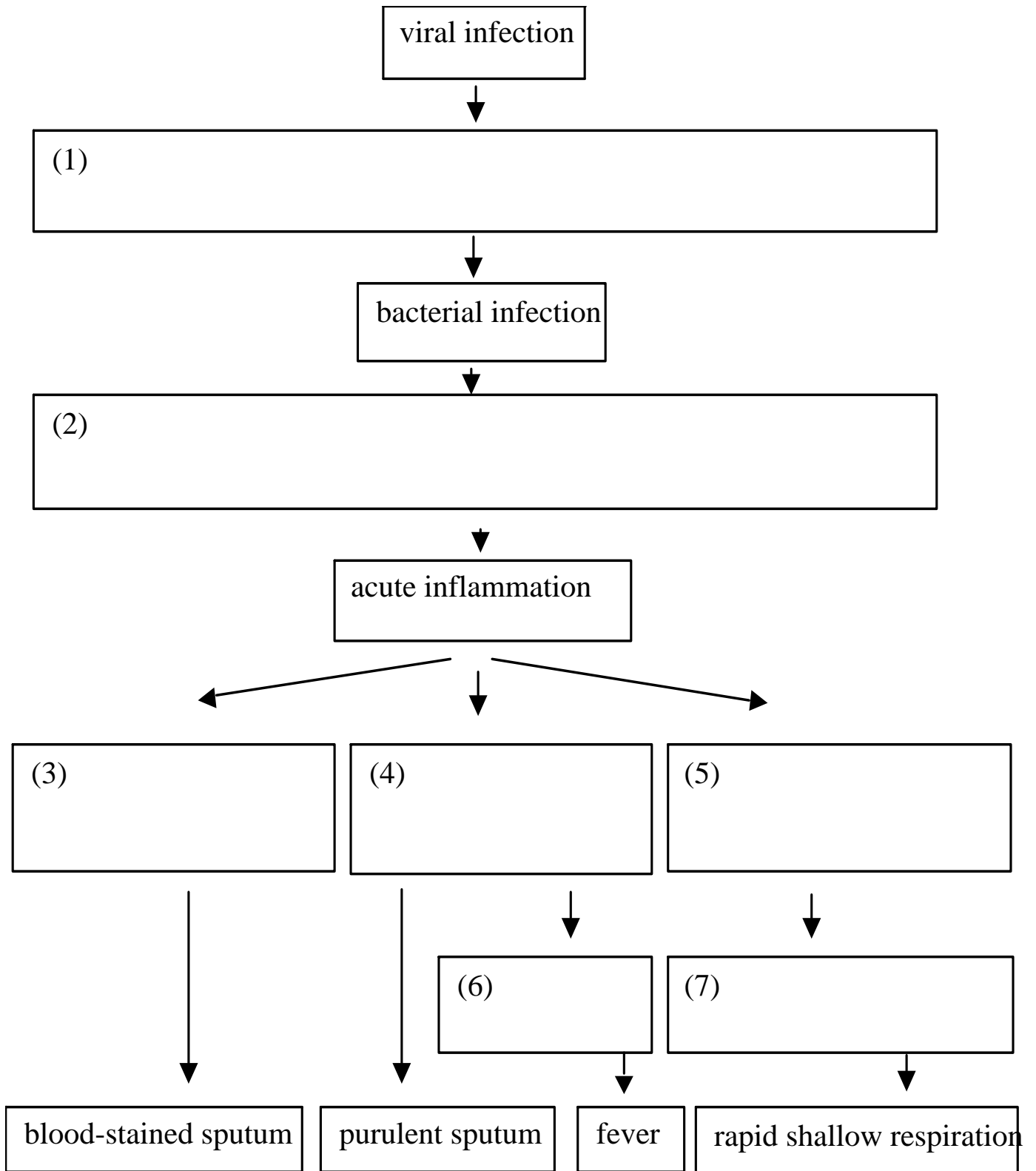
## QUESTIONS

Discuss with your colleagues, and eventually with a demonstrator, the answers to the following:

- (i) Where in the body are neutrophils formed? What route did the neutrophils take to reach the lumen of the bronchus?
- (ii) How long do leukocytes remain in the blood? What happens to them eventually?
- (iii) What would their future have been, had the tissue not been harvested?
- (iv) Are there deleterious as well as beneficial consequences of this degree of neutrophil extravasation and activation?

(v) How do you suppose a viral infection (such as influenza) of the bronchial epithelium may increase susceptibility to bacterial bronchopneumonia?

Now build up a picture of how tissue reactions to injury are initiated and how they produce effects that are recognised as symptoms (i.e. the things that the patient identifies) and the signs (i.e. the things that can be demonstrated objectively by clinical examination or various imaging methods). Fill in the empty boxes in the following flow chart, indicating the factors responsible for the progression from one stage to the next:



**INTERPRETATION OF PATHOLOGICAL CHANGES IN TISSUES AND IDENTIFICATION OF PATHOLOGICAL PROCESSES**

## AIM

The aim of this section of the class is to learn how to interpret a histological section to reveal the pathological processes and how to write a concise report describing the condition. In future classes you will be provided with a series of slides of unknown conditions and asked to write a report along the following lines. You are briefly reminded of the principles of how to look at tissue sections, which were given in the last class and then given a guide to writing a report.

### LOOKING AT TISSUE SECTIONS

- (1) Look with the **naked eye** first for distinct areas or shapes.
- (2) Use the **low power objective** to scan the section getting an overall impression of the different areas.
- (3) Using a **higher power** objective (x10, then x40) to home in on representative areas of normal or abnormal looking regions. **Identify cellular and other details**. Return to low power to see the whole picture.
- (4) Remind yourself about what the **normal tissue** should look like, at the **edge** of the section.

### DESCRIBING AND INTERPRETING PATHOLOGICAL CHANGES IN TISSUES

An essential preliminary to interpreting pathological changes in tissues is to **observe** and **describe** the topography of the tissue, i.e. the **pattern** of cellular abnormalities and the specific cellular appearance. It is helpful, therefore, to draw a simple schematic diagram and to point out, by labels, the areas of interest, which you wish to describe. Having described the key pathological features you can go on to offer an interpretation of the pathological processes and give an opinion of the nature of the disease and its possible aetiology.

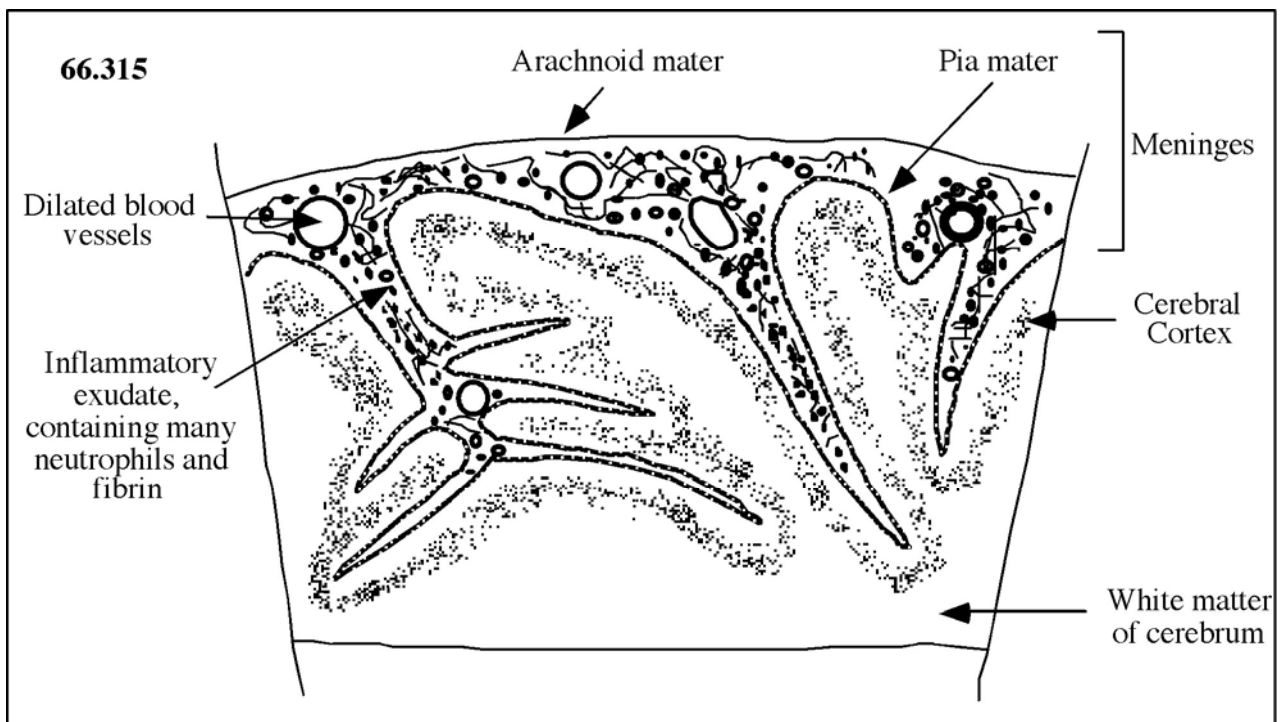
Thus:

- (1) Draw a **sketch diagram** of the whole section and where applicable a more detailed diagram of a representative abnormal area to show the cell types present etc. As everywhere else, all diagrams must have **headings** and clear **labels** with no ambiguous unlabelled structures.
- (2) Give a **description**. Referring to the above diagram, describe the distribution of the abnormality and whether there is any remaining normal tissue. Within the area of abnormality, describe the architecture of the tissue, which cell types are present and then whether these cells appear normal.
- (3) **Give an interpretation, identifying the pathological process**. Interpret the features you have described in terms of the likely processes occurring e.g., acute or chronic inflammation, granuloma formation, thrombosis, infarction, neoplasia. You may not be able to give a single overall diagnosis. However, do so if you can. The most important part is the **identification of the pathological process** (e.g. acute inflammation).

# Blank Page

**2.4 Cerebrum: unknown condition**  
**66.315**

Catalogue Number	Small Image	Image Map	Large Image
A_IN_MG_BR_23.jpg	<a href="#">Unknown condition</a>	<a href="#">Image Map</a>	<a href="#">Unknown condition</a>
A_IN_MG_BR_11.jpg	<a href="#">Unknown condition</a>	<a href="#">Image Map</a>	<a href="#">Unknown condition</a>
A_IN_MG_BR_14.jpg	<a href="#">Unknown condition</a>	<a href="#">Image Map</a>	<a href="#">Unknown condition</a>
A_IN_MG_BR_15.jpg	<a href="#">Unknown condition</a>		<a href="#">Unknown condition</a>
A_IN_MG_BR_18.jpg	<a href="#">Unknown condition</a>	<a href="#">Image Map</a>	<a href="#">Unknown condition</a>
A_IN_MG_BR_19.jpg	<a href="#">Unknown condition</a>		<a href="#">Unknown condition</a>



**Description:**

Slide 66.315 is a section of cerebrum in which the sub-arachnoid space is expanded by a dense infiltrate of cells, mostly neutrophils, but also a few large mononuclear cells, probably macrophages. The cells are within a meshwork of fine threads, which are probably fibrin. (This could be confirmed by using the trichrome stain which specifically stains fibrin scarlet). The blood vessels are dilated. The underlying cerebrum appears normal.

**Interpretation:**

The pathological process is that of acute inflammation of the meninges, acute purulent meningitis.

### SOME WORDS USED TODAY

Leukos	White	LEUKOCYTE
Cytos	Cell	
Phagein	To eat	PHAGOCYTE
Philos	Loving	EOSINOPHIL (avid for Eosin, an acid stain)
		BASOPHIL (avid for basic stains)
Lympha	Clear water	LYMPHOCYTE (originally cell of the lymph)
Mono	One	MONOCYTE, MONONUCLEAR
Poly	Many, excess	
Morphe	Form	
Nucleus	Small nut, (nux=nut)	POLYMORPHONUCLEAR

*If you are not certain what is meant by any of the words and terms used in these classes, please ask.*

### DEMONSTRATIONS

- A      Demonstration boards illustrating the development of blood cells from precursors in the bone marrow**
- B      Demonstration boards illustrating mature leukocytes in the blood**
- C      Museum specimens**

### TIDYING UP

Before leaving:  
 Dim and switch off microscope light.  
 Cover the microscope.  
 Return the wooden block if used.  
 Push the stool under the bench.

*Thank you!*

## MUSEUM SPECIMENS

**I BRAIN: Acute purulent meningitis  
P63.377**

A 66 year old man developed pneumonia, septicaemia (bacterial infection of the blood) and meningitis after a partial gastrectomy, an operation to remove a diseased part of the stomach. Why do you think each of these infections came about?

**II LUNG – Bronchopneumonia  
P71.717**

A slice of right lung showing nodules which are consolidating in some areas. A case of staphylococcal bronchopneumonia which developed in a youth with severe head injuries following a road traffic accident.

**III LUNG – Lobar Pneumonia  
21.53**

The lower and middle lobes are affected with a fibrinous membrane coating the pleura. No clinical details available.

**IV LUNG – Lobar Pneumonia  
28.205**

The upper and part of the lower lobe are affected and there is extensive pleurisy. A case of pneumococcal pneumonia and septicaemia which developed in a 34 year old woman following childbirth.

**V BRAIN: Pneumococcal meningitis  
27.28**

From a 13 year old girl who had been ill for 4 days with fever, headache and vomiting. Pneumococci were cultured from cerebro-spinal fluid. Pale, purulent exudate fills the sulci and there is generalised vasodilatation. The ventricular system is not affected by the meningitis.