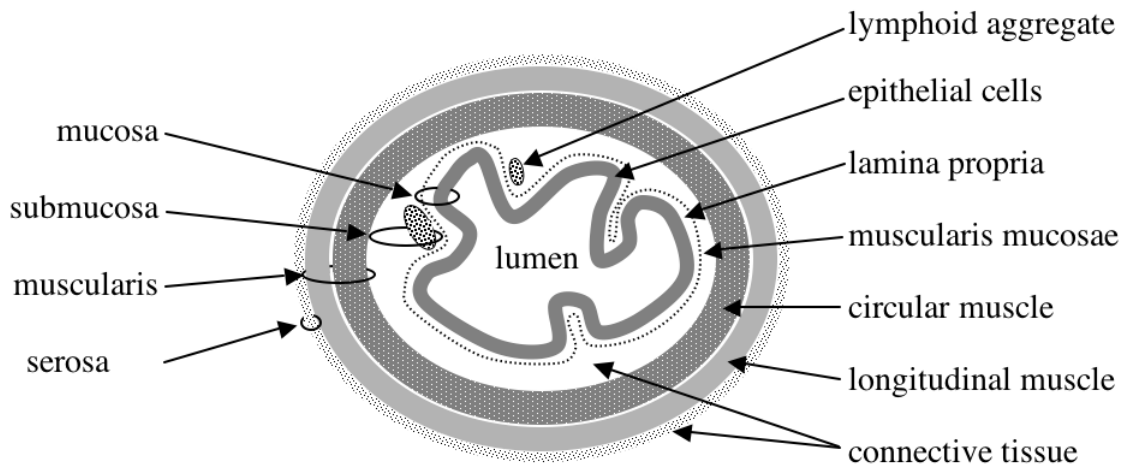


**INTRODUCTION**

This is the second of two introductory classes that aim to familiarise you with the histological appearance of healthy tissues. These classes will make it easier for you to discover disease-associated changes for yourself later in the course. Remember that all the class sheets can be accessed from the Departmental Web Site ([URL http://www.path.cam.ac.uk/partIB\\_pract/](http://www.path.cam.ac.uk/partIB_pract/)). The class sheets contain hyperlinks to labelled digital images of the specimens and slides that are shown in the classes.

**GASTRO-INTESTINAL TRACT**

The first four sections from this class are of tissues from the gastro-intestinal tract (GIT). While each region of the gastro-intestinal tract has a specific structure, all regions share basic structural features such as a 4-layered wall. These are shown in the diagram below.



**NHP2.1 Stomach : normal**  
**84.0159**

The stomach is a dilated part of the gastro-intestinal tract. The stomach wall follows the general structure shown above, with some additions and modifications. The mucosa is thrown into prominent folds named **rugae**. The mucosa contains **gastric glands** into which mucous, acid and pepsin are secreted.

Catalogue Number	Small Image	Image Map	Large Image
N_AR_ST_07.jpg	<a href="#">Normal stomach</a>		<a href="#">Normal stomach</a>

**NHP2.2 Small intestine: normal  
88.685**

Catalogue Number	Small Image	Image Map	Large Image
N_AR_SI_01.jpg	<a href="#">Normal small Intestine</a>		<a href="#">Normal Small Intestine</a>

The small intestine is specialised for the absorption of digestion products, but conforms to the general structure shown in the diagram above. To increase the surface area for absorption, finger-like processes (**villi**) project into the lumen. The villi are lined with a simple columnar epithelium. The most common cells in this epithelium are **enterocytes** (specialised for absorption) and **goblet cells** (have a clear appearance, specialised to produce mucous). Between the villi are numerous **crypts of Lieberkuhn** (often simply called **crypts** or **glands**) which produce a continuous supply of new epithelial cells that migrate up the villi before being shed or dying.

**NHP2.3 Large intestine: normal  
60.1087**

The large intestine conforms to the general structure shown in the diagram above. However, it lacks villi and consists of closely packed straight tubular **glands** or crypts (test tube-shaped) that are analogous to the crypts of the small intestine. As in the small intestine, the epithelium contains a mixture of **enterocytes** and **goblet cells**.

Catalogue Number	Small Image	Image Map	Large Image
N_AR_LI_01.jpg	<a href="#">Normal Large Intestine</a>	<a href="#">Image Map</a>	<a href="#">Normal Large Intestine</a>

**NHP2.4 Appendix: normal  
76.554**

The appendix is a small blind-ended sac that conforms to the general structural principles shown in the diagram above. It has no known absorptive or digestive function in man. In the appendix of a young person the lamina propria contains prominent **lymphoid aggregates**.

Catalogue Number	Small Image	Image Map	Large Image
N_AR_AP_08.jpg	<a href="#">Normal Appendix</a>	<a href="#">Image Map</a>	<a href="#">Normal Appendix</a>

**NHP2.5 Liver: normal  
97.220**

The liver develops during embryogenesis as an outgrowth of the gut. The principle cells of the liver are **hepatocytes**. To maximise their contact with the blood flowing through the liver, hepatocytes are arranged into roughly hexagonal **lobules**. Blood within the portal vein and hepatic artery enters at the corners of the hexagonal lobules, and percolates through a network of **sinusoids** past the hepatocytes to reach a **central vein** in the centre of each lobule. At the corners of the lobules a portal vein branch, hepatic artery branch and bile duct branch run together surrounded by connective tissue and this is called a **portal triad**.

Catalogue Number	Small Image	Image Map	Large Image
N_AR_LV_02.jpg	<a href="#">Normal Liver</a>	<a href="#">Image Map</a>	<a href="#">Normal Liver</a>

## NHP2.6 Kidney: Normal 79.475

The kidney can be divided into an outer darkly staining **cortex** and an inner lightly staining **medulla**. The cortex contains numerous knot-like **glomeruli** (clusters of capillaries) and the blood vessels (afferent and efferent arterioles) that supply them. In the glomeruli, fluids from the capillaries are filtered into the surrounding space (Bowman's capsule) and then flow into the epithelial-lined **renal tubules** (proximal convoluted tubule, loop of Henle & distal convoluted tubule – but these are difficult to distinguish histologically). In the medulla, the distal convoluted tubules coalesce into collecting ducts and eventually into the renal pelvis leading to the ureters that exit the kidney.

Catalogue Number	Small Image	Image Map	Large Image
N_UR_KD_09.jpg (a glomerulus)	<a href="#">Normal Kidney</a>	<a href="#">Image Map</a>	<a href="#">Normal Kidney</a>
N_UR_KD_06.jpg (a nephron)	<a href="#">Normal Kidney</a>	<a href="#">Image Map</a>	<a href="#">Normal Kidney</a>

## NHP2.7 Thyroid: normal 58.5

The thyroid is an **endocrine gland** that produces the hormones thyroxine, tri-iodothyronine (T4 and T3) and calcitonin. The thyroid stores the T3 and T4 hormone precursors as homogenous **thyroid colloid** within spheroidal **follicles**. The follicles are lined with a single layer of cuboidal epithelial cells. Adjacent C cells (almost impossible to see without special stains) produce calcitonin.

Catalogue Number	Small Image	Image Map	Large Image
N_NE_TH_02.jpg	<a href="#">Normal Thyroid</a>	<a href="#">Image Map</a>	<a href="#">Normal Thyroid</a>

## NHP2.8 Cerebrum (brain): normal 95.579

The cerebrum is made up of an outer layer of **grey matter** (containing **neurone cell bodies** and supporting **neuroglial cells**) and an inner central core of **white matter** (containing tracts of **nerve fibres** among supporting neuroglial cells). The cerebrum is covered by a set of membranes known as the **meninges** which contain blood vessels.

Catalogue Number	Small Image	Image Map	Large Image
N_NE_BR_01.jpg	<a href="#">Normal Cerebrum</a>	<a href="#">Image Map</a>	<a href="#">Normal Cerebrum</a>

## Class NHP2 MUSEUM SPECIMENS

### I Appendix : Normal P83.794 & 81.466

Catalogue Number	Small Image	Image Map	Large Image
N_AR_AP_10.jpg	<a href="#">Normal Appendix</a>		<a href="#">Normal Appendix</a>
N_AR_AP_11.jpg	<a href="#">Normal Appendix</a>		<a href="#">Normal Appendix</a>

### II Liver : Normal P83.636

Catalogue Number	Small Image	Image Map	Large Image
N_AR_LV_40.jpg	<a href="#">Normal Liver</a>		<a href="#">Normal Liver</a>
N_AR_LV_41.jpg	<a href="#">Normal Liver</a>		<a href="#">Normal Liver</a>

### III Kidney : Normal P83.527 & P85.701

Catalogue Number	Small Image	Image Map	Large Image
N_UR_KD_30.jpg	<a href="#">Normal Kidney</a>		<a href="#">Normal Kidney</a>
N_UR_KD_31.jpg	<a href="#">Normal Kidney</a>		<a href="#">Normal Kidney</a>

### **TIDYING UP**

#### **Before leaving:**

**Switch off your microscope light. Cover the microscope.  
Return the wooden block, if used. Push your stool under the bench.**

***Thank you!***